



Evaluation of Acute Pulmonary Embolism Using Spiral CT scan

KEYWORDS

Acute, Pulmonary, Embolism, Spiral CT scan, Sudan

Mohammed Yousef

College of Medical Radiologic Sciences, Sudan University of Science and Technology.P.O.Box 1908, Khartoum, Sudan

* Moawia Gameraddin

Alzheim Alazhari University, Faculty of Radiological Sciences and Medical Imaging.P.O.Box1432 Khartoum Bahri 13311-Sudan, * Corresponding Author

Jumaa Tamboul

College of Medical Radiologic Sciences, Sudan University of Science and Technology.P.O.Box 1908, Khartoum, Sudan

Suliman Salih

Taibah University , College of Medical Applied Sciences, Department of Diagnostic Radiologic Technology, Fax: 8475790 P.O: 30001 AlmadinahAlmunawwarah , KSA

Ikhlas Abdelaziz

College of Medical Radiologic Sciences, Sudan University of Science and Technology.P.O.Box 1908, Khartoum, Sudan

Sultan Alshoabi

National Cancer Institute - University of Gezira, Sudan

ABSTRACT *Objectives: The study aimed to determine the role of spiral CT Angiography in suspected cases of Acute Pulmonary Embolism. Material and methods: The study was conducted at EL-Nilain center , Royal care center and Faisal center. Fifty patients of suspected pulmonary embolism (PE) from (August –November 2011), had been selected randomly of different ages and genders underwent spiral CT angiography from the level of arch of aorta to the dome of diaphragm. Scanning was done using Siemens CT machine. Results: Out of 50 patients, there were 38 (76%) positively identified with pulmonary embolism, moreover females (68%) were most likely presented with PE, the right pulmonary artery was more affected. The peak incidence age ranged between 40-60years (32%), Shortness of breath is the most clinical indication with (54%) incidence; half of the patient were presented with DVT, Consequently on CTA 12% of patients with PE showed plural effusion, 20%with consolidation collapse and cavities. Conclusion: The study confirmed that, the spiral CT scanner is very effective modality in detection of pulmonary embolism , since it is non –invasive procedure , and has a high specificity , so it is preferred and used as the first line of investigations in diagnosing of Pulmonary embolism .*

INTRODUCTION

Pulmonary embolism (PE) was clinically described in the early 1800s, and von Virchow first described the connection between venous thrombosis and PE.(Boyden, 1955 and Mitchell ,1997) In 1922, Wharton and Pierson reported the first radiographic description of PE.[Wharton and Pierson,1922)

Imaging has played an important role in the diagnosis of PE. For many years, ventilation-perfusion (V/Q) scintigraphy has been the main imaging modality for the evaluation of patients with suspected PE. However, with the advent of and the widespread availability of faster computed tomography (CT) scanners, CT scanning has emerged as another important diagnostic test for the evaluation of not only PE, but also of deep venous thrombosis (DVT) in select patients.

Three primary influences predispose a patient to thrombus formation; these form the so-called Virchow triad: (1) endothelial injury, (2) stasis or turbulence of blood flow, and (3) blood hypercoagulability.

More than 90% of all PEs arise from thrombi within the large deep veins of the legs, typically the popliteal vein and the larger veins above it.(Remy-Jardin. et al, 2007) The pathophysiologic consequences of thromboembolism in the lung largely depend on the cardiopulmonary status of the patient and on the size of the embolus, which, in turn, dictates the size of the occluded pulmonary artery.

Pulmonary embolism is a common cardiovascular emergency.

According to data collected between 1979 and 1999, the prevalence among hospitalized patients in the United States was 0.4%.[Stein et al, 2005] The true prevalence of venous thromboembolism is underestimated, as many cases are not apparent clinically, and unsuspected PE can be found on up to 3.4% of inpatient and 0.9% of outpatient CT scans.[Storto et al,2005] From 2000-2007, the incidence of pulmonary embolism increased from 0.69 to 0.91 per 100 admissions, in strong correlation with increased use of pulmonary CTA.(Sheh and Bellin,2012)

Mortality attributable to PE occurs in approximately 2-6% of patients with hemodynamically stable PE and in 30% or more of patients presenting with hemodynamic instability. [Wood,2002] Overall mortality has not changed with the shift to CTA for PE diagnosis; however, the case-fatality rate decreased from 5.7% to 3.3%.[Sheh, and Bellin,2012]The case-fatality rate decrease suggests that the recent shift from V/Q scintigraphy to pulmonary CTA has been associated with a less fatal spectrum of embolic disease.

In patients with possible PE, chest radiographic findings may indicate if lung scanning (V/Q) or helical CT scanning should be the next method of evaluation. If the chest radiograph is normal, V/Q findings may be diagnostic; if the chest radiograph is abnormal, helical CT should be performed.[Patel, 2005 and Stein et al,2007]

A quantitative D-dimer assay is reported to have high negative predictive value and may be effective for excluding the need for pulmonary CT angiography (CTA) in selected

cases.[Abcarian et al, 2004] Another study shows that using a clinical decision rule with D-dimer level improved pulmonary CTA and better identified positives for pulmonary embolisms.[Soo Hoo et al, 2011].

Conventional pulmonary angiography is invasive, time consuming, and more expensive than other tests. The role of conventional angiography is limited to patients in whom other results are nondiagnostic or the clinical suspicion is high.[Silverstei et al, 1998 and Doshi, et al ,2008] In patients with suspected DVT, the workup should start with leg ultrasonography.

Technical advances in CT scanning, including the development of multidetector-array scanners, have led to the emergence of CT scanning as an important diagnostic technique in suspected PE.[Yankelevitz et al, 2000 and Yasui et al, 2007]. Contrast-enhanced CT scanning is increasingly used as the initial radiologic study in the diagnosis of PE, especially in patients with abnormal chest radiographs in whom scintigraphic results are more likely to be nondiagnostic.(Patel,2005 and Stein et al,2007).

This study aimed to check the role of spiral CT in the detection of pulmonary embolism practically and to explain the suitable protocol that used to demonstrate the pulmonary embolism in spiral CT.

2. Materials & Methods

This study was a practical study done in ZITONA, FIESAL, FEDAIL and ALNELAIN Center radiographic departments, Data were collected in the period from (10.8.2011) to (30.10.2011).

Study population: There were 50 patients in different genders & different ages with clinically suspected acute PE had been enrolled. All patients were examined by using spiral CT. There were 34 patients were females while the 16 were males and their ages are ranged from 20 to 70 years old.

Technique and Procedure:

A significant advantage of spiral CT data acquisition is application to 3D imaging of vascular structures with an intravenous injection of contrast medium. This application CT angiography (CTA) is defined as 'any CT imaging of blood vessels that has been opacified by a contrast medium.

During spiral data acquisition, the entire area of interest can be scanned during the injection of contrast. Images can be captured when vessels are fully opacified to demonstrate either arterial or venous phase enhancement through the acquisition of both data sets (arterial and venous). In particular, CTA techniques are useful in imaging the abdominal and thoracic aorta (Renal and pulmonary arteries)

2.1 Requirements:

At least four major steps are crucial to carrying out a CT pulmonary angiography (CTA) examination, careful execution of these steps will serve to optimize the examination and produce high –quality images that will aid the radiologist in making an accurate diagnosis. These steps include patient preparation, acquisition parameters, contrast medium administration and post – processing.

2.2 Patient preparation

A successful CTA examination depend on careful preparation of the patient before the examination .Such preparation requires that both the technologist and radiologist work together to obtain the appropriate and correct information from the patient and to ensure that the patient understand the procedure , particularly breath- hold technique . Preceding the CTA a patient history was obtained to identify patients with history of iodine allergy, renal dysfunction, cardiac disease and asthma. Steroid pre-medication was administrated to that patient with a history of iodine allergy

or previous reaction to iodinated contrast agents. Patient with a history of renal dysfunction were further evaluated with creatinine. level and blood urea nitrogen level which should be assessed before the procedure patient were instructed on breath –holding technique and practicing with the patient , before the examination ,helped in providing a successful motion free examination . Hyperventilation was performed immediately before the examination that facilitates patient breath-holding ability.

2.3 Acquisition Parameter:

The CTA has been determined a number of parameter were carefully chosen to optimize both the quality of the imaging and the accuracy of the CTA examination. These parameters include the total spiral scan time T(sec), the slice thickness S (mm) and the speed of the patient through the gantry with is the table speed D(mm/sec) .Also influencing the quality of the CTA examination was upon careful selection of kV_p and mA values and the images reconstruction intervals, 120 kV_p was commonly used. The mA values selected were based on the size of the patient's body section to be imaged. The image reconstruction interval referred to the spacing between the center of the slice and they were important because they play a great role in the quality of the 3D-CTA images

2.4 Contrast Medium Administration:

Imaging the contrast while it was in vascular area of interest during the CTA examination was a critical step in the acquisition of images. Contrast injection techniques took into consideration. The volume of contrast needed to enhance vascular regions, the contrast injection rate , and the timing between the start of contrast medium injection and the start of the spiral scan. Measuring the contrast circulation times for different patient was important in CTA to ensure that imagings were recorded when flow-in of contrast was optimum in the pulmonary arteries.

2.5 Post processing technique:

2.5.1 Visualization tool:

The a logarithm used to display 3D images from the axial data set was post processing technique or visualization tool which were used quite extensively in CTA currently , the following technique was common -place in CTA .

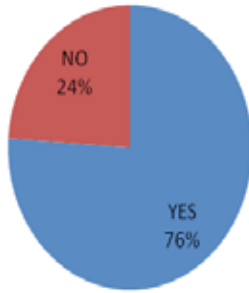
2.5.2 Multi-planar reconstruction (MPR)

MPR was the first visualization tool used in CTA. It was simple and faster to reconstruct than any other 3D technique and enabled visualization of the volume data set in any plane including curved planes.

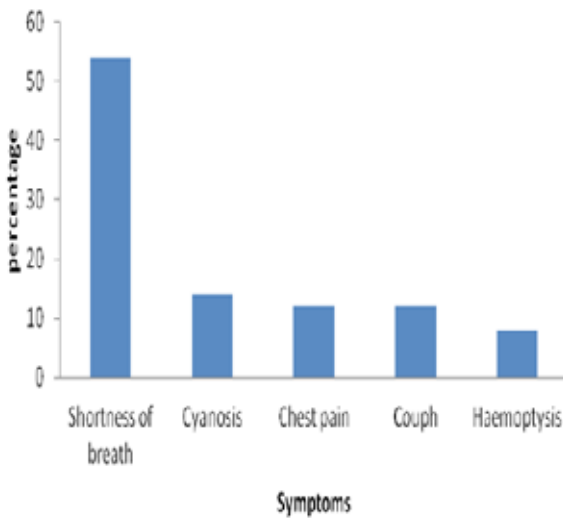
3. Results

Out of 50 patients, there were 38 (76%) positively identified with pulmonary embolism figure (1) , moreover females(68%) were most likely presented with PE males (32)Additionally during the study , it was noted that the right pulmonary artery was affected more than the left pulmonary artery . The peak incidence was among the age between 40-60 years of age presenting the percent of (32%). Shortness of breath is the most clinical indication with (54%) incidence, followed by Cyanosis (14%), Chest pain (12%), Cough (12%), and Haemoptysis figure (2), From total population nearly half were presented with DVT ,Consequently on CTA 12% of patients with PE showed plural effusion, 20%with consolidation collapse and cavities. figure (3), spiral CT Angiography images presentation of of Acute Pulmonary Embolism (Figure4,5,6)

Pulmonary Embolism present within sample population

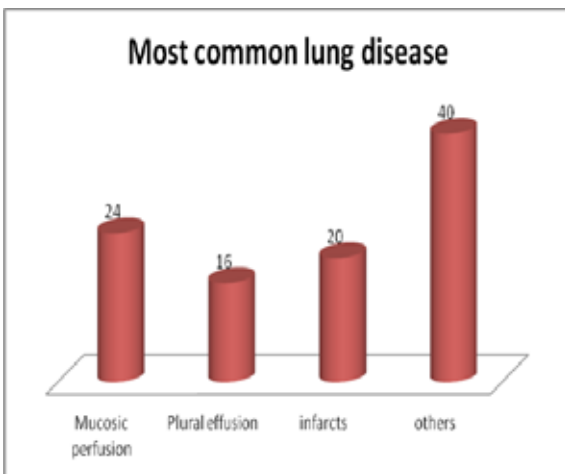


common symptoms



Figure(2): shows the Clinical symptoms of the study population Source: researcher data

Most common lung disease



Figure(3):shows the Clinical symptoms of the study population

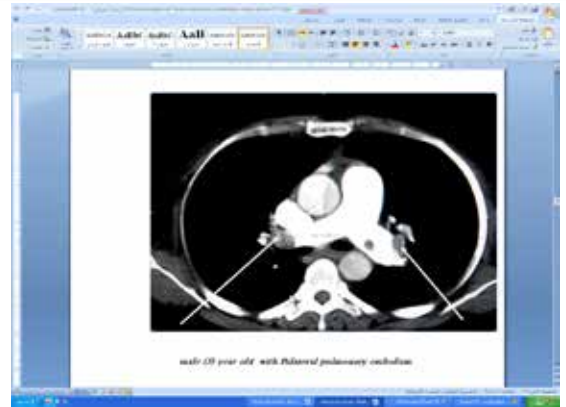


Figure (4) male 61 with Bilateral pulmonary embolism

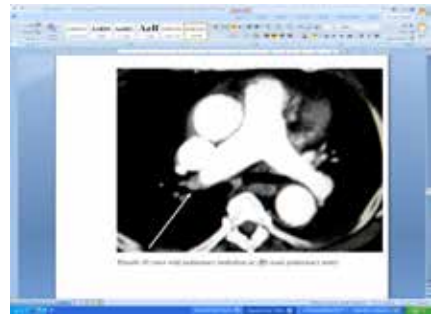


Figure (5) Female 37 years with pulmonary embolism in (Rt) main pulmonary artery

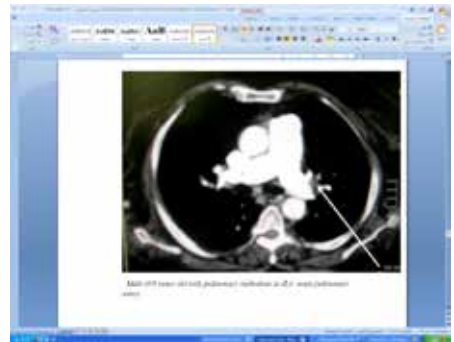


Figure (6) Male 58 years with pulmonary embolism in (Lt) mainpulmonary artery

Discussion

This study was performed in 50 patients , 34 were females while 16 were males and their ages are ranged from 20 to 70 years old. They had been referred for CT chest examination. The prevalence of PE in this study population was 76% (38 of 50 patients) during the study period. The Common presenting symptoms were shortness of breath , cyanosis , chest pain and hemoptysis. Most of those patients were presented with short duration of symptoms (less than 6 hours). From total population nearly half were presented with DVT Consequently on CTA 12% of patients with PE showed plural effusion, 20%with consolidation collapse and cavities. From the total sample population , only 38 where significantly positive for PE . Furthermore , the former population was distributed according to dilatation of pulmonary artery into RT pulmonary artery and Lt pulmonary dilatation of pulmonary artery .Where 30 patients presented with RT pulmonary artery dilatation while only 8 patients with Lt pulmonary artery . Frequency of Pulmonary Embolism was higher within females (28) than males (10) . This result indicates that CT has a high technical success rate. The characteristic of the all variables in the sample studied were described as frequencies and percentages. CT chest uses axial and coronal slice sections

to demonstrate PE, so CT scanning of chest providing great clarity and reveal high details in diagnosing of PE.

The study findings demonstrate that CT is useful in the diagnosis of PE. In this study, we found an overall prevalence of 76% of PE among 50 patients who underwent routine thoracic CT examinations. We believe that multiple factors contributed to a missed diagnosis of PE in our sample, including the relatively small size of affected pulmonary arteries in most cases and the limited extent of involvement. Our results emphasize the importance of a heightened awareness of PE in pediatric oncology patients, especially those with coagulation disorders and a history of deep venous thrombosis or PE. We did not find a significant association between the presence of PE and a specific type of symptoms. We acknowledge several limitations of our study. First, a number of CT scans were excluded from analysis, most commonly because of suboptimal contrast enhancement. Cases with suboptimal contrast enhancement have been similarly excluded in previous studies of unsuspected PE in adults (Patel et al,2003).

Finally, CT is a technical improvement of helical CT and a diagnostic tool with a high sensitivity and specificity for the detection of PE. Our experience indicates that helical CT could replace pulmonary arteriography for the direct demonstration of endoluminal thrombi in the pulmonary arteries in a majority of patients. Selective pulmonary arteriography should be reserved for selecting patients with an unresolved diagnosis. The evaluation of small vessels, which is improved by thin sections, remains a limitation of current helical CT. However, the development of faster imaging systems (with multi-section or multiple-array detectors) with sub-millimeter isotropic imaging are expected to improve the evaluation of sub-segmental pulmonary vessels, with optimal spatial and temporal resolution, in the near future. In the present study, we investigated prospectively the diagnostic performance of pulmonary MDCT angiography alone in consecutive patients suspected of having PE. Our major findings were that CT had a high sensitivity. With regard to sensitivity, specificity, and accuracy, we found good agreement with a previous retrospective study [Kyrle,2008], which found values of 86%, 98%, 93%, respectively, for MDCT. The sensitivity found for pulmonary MDCT angiography was 83% [Reinartz et al, 2004]. We had a slightly lower sensitivity of 68% for MDCT. We have no obvious explanation for the difference in sensitivity, but the differences in study populations and algorithms for final diagnosis may have been contributing factors. Taken together, we found that CT in diagnosis pulmonary embolism useful as a first-line routine test for PE, with excellent diagnostic performance. At present, many centers use only pulmonary MDCT, but this might be suboptimal because of its possible lower sensitivity and

higher radiation dose. Reasons for extensive use of MDCT may include its round the-clock availability, its lower cost, its high frequency of conclusive results. Recently proposed algorithms for imaging evaluation of patients suspected of having PE have omitted V/Q scintigraphy from the work-up, and some guidelines considered V/Q scintigraphy only as an alternative when patients cannot undergo MDCT because of severe renal insufficiency or allergy to intravenous contrast agents or when a CT-based strategy is inconclusive [Patel et al,2003]. A total of 46 patients (24%) were excluded from the present study because of renal dysfunction, indicating that MDCT may not be an option in many patients. This is an important strength of a scintigraphic approach.

5. Conclusion

In conclusion, helical CT is a technical improvement of helical CT and a diagnostic tool with a high sensitivity and specificity for the detection of PE. These findings of study indicate that helical CT could replace pulmonary arteriography for the direct demonstration of endoluminal thrombi in the pulmonary arteries in a majority of patients. Selective pulmonary arteriography should be reserved for select patients with an unresolved diagnosis. The evaluation of small vessels, which is improved by thin sections, remains a limitation of current helical CT. However, the development of faster imaging systems with submillimeter isotropic imaging are expected to improve the evaluation of sub-segmental pulmonary vessels, with optimal spatial and temporal resolution, in the near future.

This modern equipment CT has diagnosing function and resulting in good high technical properties and this powerful procedure must be one important interests of our planning to progress and develop our medical services in the Sudan.

CT is the image modality of choice evaluate PE, as the provides 'a road map', and excellent detail is available regarding to the anatomy, pathology and early diagnosis of PE very import factor in the disease management.

CT was used ideally for full evaluation of the PE and today CT scanners allow post processing reformat for further views in different planes if required.

With multi-detector row CT technology, past limitations of CT for the diagnosis of PE should be effectively overcome; for all practical purposes, CT has become the first-line modality for imaging in patients suspected of having PE.. However, prospectively acquired patient outcome studies are still needed. Once this type of investigation has confirmed that a negative CT study can be used to safely rule out PE, we believe use of CT to aid in diagnosis of PE will be unanimously accepted

REFERENCE

1. Abcarian PW, Sweet JD, Watabe JT, Yoon HC(2004). Role of a quantitative D-dimer assay in determining the need for CT angiography of acute pulmonary embolism. *AJR Am J Roentgenol.*;182(6):1377-81.[Medline]. [Full Text].
2. Boyden EA. Segmental Anatomy of the Lungs (1955): Study of the Patterns of the Segmental Bronchi and Related Pulmonary Vessels. New York, NY: McGraw-Hill;;23-32.
3. Doshi SK, Negus IS, Oduko JM (2008). Fetal radiation dose from CT pulmonary angiography in late pregnancy: a phantom study. *Br J Radiol.* Apr 14;[Medline].
4. Mitchell RN, Kumar V. Hemodynamic disorders, thrombosis, and shock. In: Kumar V, Cotran RS, Robbins SL, eds. *Basic Pathology*, 6th ed. Philadelphia, Pa: WB Saunders; 1997:60-80
5. Kyrle PA, Eichinger S. New diagnostic strategies for pulmonary embolism(2008). *Lancet.*;371:1312-1315
6. Patel S, Kazerooni EA.(2005) Helical CT for the evaluation of acute pulmonary embolism. *AJR Am J Roentgenol.* Jul;185(1):135-49. [Medline]. [Full Text]
7. Remy-Jardin M, Pistolesi M, Goodman LR, et al. Management of suspected acute pulmonary embolism in the era of CT angiography(2007): a statement from the Fleischner Society. *Radiology.* Nov;245(2):315-29.[Medline]. [Full Text].
8. Patel S, Kazerooni EA, Cascade PN. Pulmonary embolism(2003): optimization of small pulmonary artery visualization at multi-detector row CT. *Radiology.* May;227(2):455-60. [Medline].
9. Reinartz P, Wildberger JE, Schaefer W, Nowak B, Mahnenk AH, Buell U. Tomographic imaging in the diagnosis of pulmonary embolism(2004): A comparison between V/Q lung scintigraphy in SPECT technique and multislice spiral CT. *J Nucl Med.*;45:1501-1508
10. Stein PD, Beemath A, Olson RE. Trends in the incidence of pulmonary embolism and deep venous thrombosis in hospitalized patients. *Am J Cardiol.* Jun 15 2005;95(12):1525-6. [Medline]
11. Storto ML, Di Credico A, Guido F, Larici AR, Bonomo L (2005). Incidental detection of pulmonary emboli on routine MDCT of the chest. *AJR Am J Roentgenol.* Jan;184(1):264-7. [Medline].
12. Sheh SH, Bellin E, Freeman KD, Haramati LB. Pulmonary embolism diagnosis and mortality with pulmonary CT angiography versus ventilation-perfusion scintigraphy: evidence of overdiagnosis with CT? *AJR Am J Roentgenol.* Jun;198(6):1340-5. [Medline]
13. Stein PD, Woodard PK, Weg JG, et al (2012). Diagnostic pathways in acute pulmonary embolism: recommendations of the PLOPED II Investigators. *Radiology.* Jan 2007;242(1):15-21. [Medline]. [Full Text].
14. Soo Hoo GW, Wu CC, Vazirani S, Li Z, Barack BM. (2011) :Does a Clinical Decision Rule Using D-Dimer Level Improve the Yield of Pulmonary CT Angiography?. *AJR Am J Roentgenol.* May;196(5):1059-64.[Medline]
15. Silverstein MD, Heit JA, Mohr DN, et al. (1998). Trends in the incidence of deep vein thrombosis and pulmonary embolism: a 25-year population-based study. *Arch Intern Med.* Mar 23;158(6):585-93. [Medline]. [Full Text]
16. Stein PD, Fowler SE, Goodman LR, et al(2006). Multidetector computed tomography for acute pulmonary embolism. *N Engl J Med.*;354:2317-2327
17. Whart on LR, Pierson JW.(1922): Minor forms of pulmonary embolism after abdominal operations. *JAMA.*;79:1904-1
18. Wood KE. Major pulmonary embolism(2002): Review of a pathophysiologic approach to the golden hour of hemodynamically significant pulmonary embolism. *Chest.* Mar;121(3):877-905. [Medline]
19. Yankelevitz DF, Gamsu G, Shah A, et al (2000). Optimization of combined CT pulmonary angiography with lower extremity CT venography. *AJR Am J Roentgenol.* Jan;174(1):67-9. [Medline]. [Full Text]
- 20- Yasui T, Tanabe N, Terada J, et al (2007). Multidetector-row computed tomography management of acute pulmonary embolism. *Circ J.* Dec;71(12):1948-54. [Medline]. [Full Text]