

***In vivo* Study on Lead, Cadmium and Zinc Supplementations on Spermatogenesis in Albino Rats**

¹A.M. Abdella, ²B.H. Elabed, ³A.O. Bakhiet, ⁴W.S.A. Gadir and ⁵S.E.I. Adam

¹Department of Clinical Chemistry, Collage of Medical Laboratory Science, University of El Neelain, P.O. Box 12702 Khartoum, Sudan

²Department of Clinical Chemistry, Collage of Medical Laboratory Science Sudan University of Science and Technology, Khartoum, Sudan

³College of Veterinary Medicine, Sudan university of Science and Technology, Sudan

⁴Food Center, Ministry of Science and Technology, Sudan

⁵Faculty of Science and Technology, University of El Neelain, Khartoum, Sudan

Corresponding Author: A.M. Abdella, Department of Clinical Chemistry, Collage of Medical Laboratory Science, University of El Neelain, P.O. Box 12702 Khartoum, Sudan

ABSTRACT

This study was designed to elucidate the mechanisms accounting for disruption of the normal spermatogenesis in the testis, exposed to various levels of cadmium (Cd), lead (Pb) and zinc (Zn). Forty two mature male Albino rats, were divided into six groups; group 1 treated with 100 mg Cd kg⁻¹ diet, group 2 treated with 5 mg Pb kg⁻¹ diet, group 3 with 50 mg Zn kg⁻¹ diet, group 4 treated with mixture of 5 mg Pb +50 mg Cd kg⁻¹ diet, group 5 treated with 50 mg Cd + 25 mg Zn kg⁻¹ diet and group 6 treated with 5 mg Pb +25 mg Zn kg⁻¹ diet for three month. Group 7 was kept as control. Significant increased (p<0.05), of both blood Cd and Pb with loss of both weight and hair associated with testicular enlargement in rats dosed with Cd and/or Pb in the diet. As a consequence these groups showed blockage of spermatogenesis at seminiferous tubules level, maturation arrest and proliferation of the sertoli cells. Where as the group treated with Zn, showed increased weight and increased number of germs cells and developing spermatide in the testicular level. The combined diet of Cd with Pb in one dose exacerbated the toxic action of these elements. While mixing of Zn with Cd and Pb reduced the toxicity of these elements and their effects on development of the germ cell and the proliferation of the sertoli cells.

Key words: Sertoli cells, sperms maturation, seminiferous tubules, cadmium, lead, zinc

INTRODUCTION

There is an evidence of trends with time of an increased frequency of male tumours, malformations and other anomalies and decline in semen quality. Study of testicular biopsies showed wide geographic variations which, may be caused by climate or environmental pollution (Rutstein and Shah, 2004). Male reproductive function in the general population has attracted increasing attention due to reports suggesting that the occurrence of several toxicants affecting the male genital tract have increased during the last 50 years (Batra *et al.*, 2004). These include an increased incidence of testicular cancer and some congenital anomalies, such as cryptorchidism or hypospadias and an apparent decline of sperm production in the overall male population. Such events have been tentatively linked to the widespread use of chemicals. Humans are exposed to

many environmental agents that may be hazardous to their reproductive capacity. Male reproductive function is known to be highly sensitive to many chemicals and physical agents generated by industrial or agricultural activities. Such agents are commonly present in some occupational activities and in the general environment (Batra *et al.*, 2004).

Lead (Pb) is a heavy metal that is naturally distributed in small amounts on the surface of the earth. Lead exposure is still among the most important environmental health problems worldwide; gasoline is the most important source of lead (Goldman, 2000).

Pb is a classic example of a toxicant that directly affects the neuroendocrine system. Exposure to lead for less than one year will cause elevation of serum LH, ABP reduced total and free testosterone concentration (Goldman, 2000).

There are three main ways that people can still be exposed to lead, in the general environment, in the workplace and at home (Public Health Service, 2000).

Lead can affect many body systems in both children and adults. The health effects of lead depend upon the amount of exposure, which is determined by three factors: intensity, duration and timing. Intensity refers to the relative degree of exposure (small, moderate, or large) at any given time (Marshall, 1995). Duration refers to the time course over which the exposure occurs (days to years). Timing refers to the developmental stage at which the exposure occurs. Another important factor that may influence the health effects of lead exposure is the nutritional status of the child. It has been shown that diets low in calcium and iron can actually increase the amount of lead the body absorbs (Morton *et al.*, 1974; Osman *et al.*, 1998).

Cadmium (Cd) is a naturally occurring metallic element that is used for electroplating and galvanization processes, in the production of pigments, in batteries, as a chemical reagent and in miscellaneous industrial processes. Cadmium compounds have varying degrees of solubility ranging from very soluble to nearly insoluble (Elinder *et al.*, 1976). The solubility affects their absorption and toxicity. Exposure to Cd and Cd compounds may occur in both occupational and environmental settings, the latter primarily via the diet and drinking water. Developmental and reproductive toxicity in humans have not been demonstrated for oral exposure to Cd (Elinder *et al.*, 1976). But in animals, developmental toxicity for cadmium administered orally is equivocal. Few, if any exposed to cadmium chloride in the drinking water during gestation and teratogenic effects (fused or absent legs) following gavage administration of cadmium during gestation. Neurological effects in pups were detected following gestational exposure (Ellenhorn *et al.*, 1997).

Zinc (Zn) has many biologically significant interactions with hormones. It plays a role in the production, storage and secretion of individual hormones as well as in the effectiveness of receptor sites and end-organ responsiveness (Bishop *et al.*, 1996). Among the most notable effects of Zn deficiency on hormone production and secretion are those related to testosterone, insulin and adrenal corticosteroids, spermatogenesis and the development of the primary and secondary sex organs in the male and all phases of the reproductive process in the female can be adversely affected by Zn deficiency (Inslar and Lunenfeld, 1993). The major abnormality in the male is testicular hypofunction affecting both spermatogenesis and the production of testosterone by the Leydig cells. Male fertility Zinc is implicated in normal prostate functions and male infertility (Zorbas *et al.*, 1997). Male reproductive function is highly sensitive to many chemicals and physical agents generated by industrial or agricultural activities. Such agents are commonly present in some occupational activities and in the general environment. This study was designed to elucidate the mechanisms accounting for disruption of the normal spermatogenesis in the testis, exposed to various levels of cadmium (Cd), lead (Pb) and zinc (Zn).

MATERIALS AND METHODS

Forty two adult Albino male rats, age range 3-4 month and weight range 80-130 g were housed within the premises of the Medicinal and Aromatic Plants Research Institute, National Center for Research, Khartoum, under illumination at night and early morning with feed and drinking water provided *ad libitum*. The rats were allotted at random to seven groups, each of 6 rats. Group 1 treated with 100 mg Cd kg⁻¹ diet, group 2 treated with 5 mg Pb kg⁻¹ diet and group 3 treated with 50 mg Zn kg⁻¹ diet. Group 4 treated with mixture of (5 mg Pb+50 mg Cd) kg⁻¹ diet, group 6 treated with a mixture of (50 mg Cd+25 mg Zn) kg⁻¹ diet and group 6 treated with mixture of (5 mg Pb +25 mg Zn) kg⁻¹ diet. Group 7 was served as control group.

The test groups and their control were kept on the prescribed treatment for three month (March to July/2008) with continuous observation of their weight, clinical feature and genital abnormalities. Albino rats were sacrificed and their blood and serum was collected for assessment of Cd, Pb and Zn level using Atomic Absorption Spectrometer (AAS) (Bishop *et al.*, 1996).

At necropsy, all rats were examined to identify gross lesions and specimens of the testis were fixed in 10% neutral buffered formalin and processed for histopathology (Bancroft *et al.*, 1996).

Statistical methods: Most of the data were expressed in mean, standard error and standard deviation and analyzed by student t-test, with significant fixed at p<0.05.

RESULTS

The albino rats dosed 100 mg Cd kg⁻¹ diet and 5 mg Pb kg⁻¹ diet Pb single or mixture in the diet showed decreased weight in the third month, associated with hair loss and testicular enlargement. Where as the group that was treated with 50 mg Zn kg⁻¹ diet has recorded increases of weight.

Blood Cd was slightly decreased in group treated with Zn, slightly increased in group dosed with Cd+Zn and significant Increased in both groups treated with Cd alone (0.06 versus 0.25, p<0.01), or with Pb element (0.08 versus 0.23, p<0.05).

Blood Pb level in Albino rats , was slightly decreased in group treated with Zn, slightly increased in group dosed with Pb+ Zn and significantly increased in groups treated with Pb alone (0.8 versus 3.5, p<0.05) or with Cd element (0.8 versus 3.5 µg L⁻¹, p<0.01).

Serum Zn level slight decrease in rats treated with Pb+Zn, Pb, significant increased was observed in the groups treated with Zn (0.16 versus 3.1 mg dL⁻¹, n = 6, p<0.01) and significantly decreased in the groups treated with both Cd (0.16 versus 0.12 mg dL⁻¹, n = 6, p<0.01) and Pb (0.16 versus 0.12, n = 6, p<0.01) alone and mixture of the two elements (0.16 versus 0.06, n = 6, p<0.01).

Histopathological study of control untreated adult male Albino rats, showed normal development of the germs cell inside the seminiferous tubules and normal scatter of the seritoli-cells (Fig. 1).

Mature male Albino rats treated with 100 mg Cd kg⁻¹ diet shows moderate blockage of spermatogenesis at seminiferous tubules level (Fig. 2). Treatment of rats with 5 mg Pb kg⁻¹ diet, illustrated severe blockage of spermatogenesis at seminiferous tubules level with severe maturation arrest and proliferation of sertoli cells (Fig. 3).

Increased number of germs cells and developing spermatide at seminiferous tubules level in the test group treated with 25 mg Zn kg⁻¹ diet (Fig. 4). Treatment with (5 mg Pb+50 Cd mg kg⁻¹) diet, caused partial maturation arrest and proliferation of the sertoli cells with slight blockage of spermatogenesis at seminiferous tubules level (Fig. 5). As illustrated in Fig. 6, test group treated

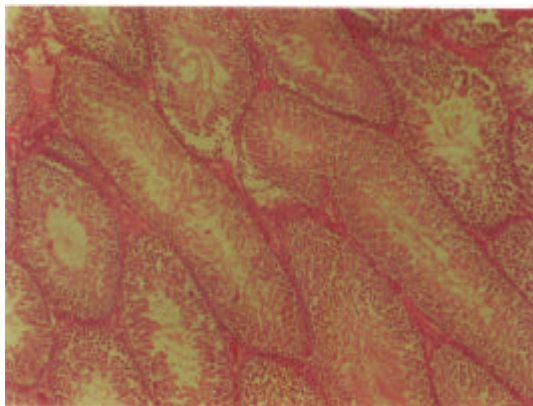


Fig. 1: Testicular seminiferous tubules, germ cells, spermatogenesis and seritoli cells of the control group H and E x40

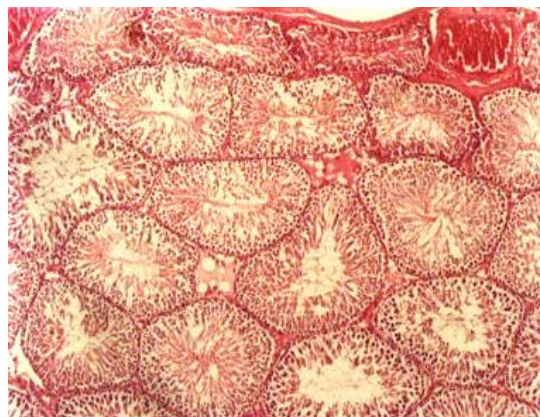


Fig. 2: Mature male Albino rats treated with 100 mg Cd kg⁻¹ diet shows moderate blockage of spermatogenesis at seminiferous tubules level. H and E x40

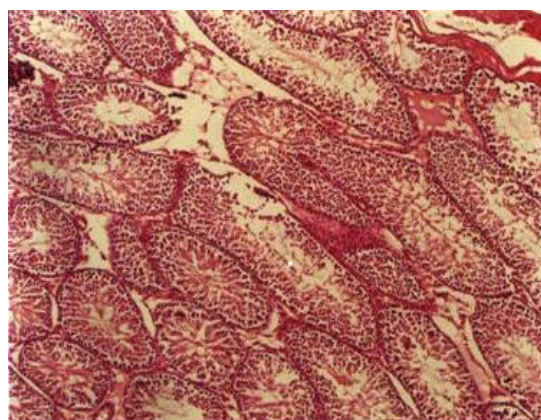


Fig. 3: Treatment of rats with 5 mg Pb kg⁻¹ diet, illustrated severe blockage of spermatogenesis at seminiferous tubules level with severe maturation arrest and proliferation of sertoli cells. H and E x40

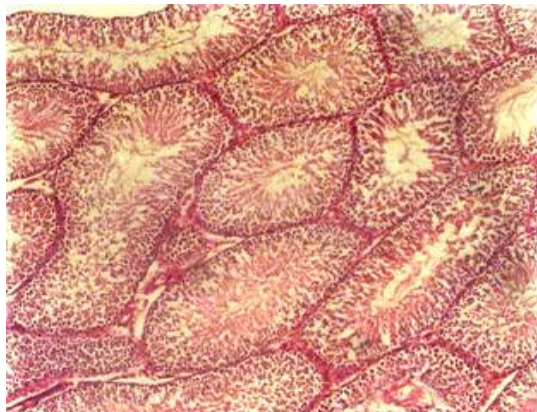


Fig. 4: Increased number of germ cells and developing spermatides at seminiferous tubules level in the test group treated with 25 mg Zn kg⁻¹ diet. H and E x40

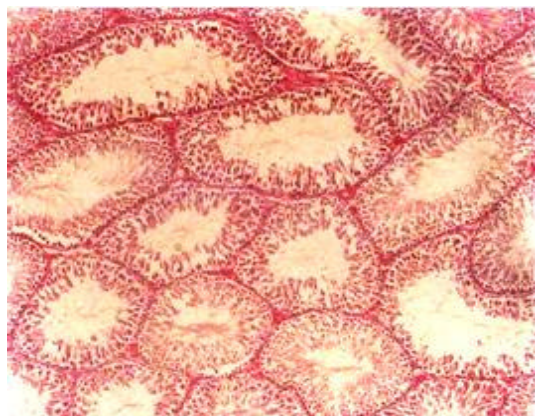


Fig. 5: Partial maturation arrest and proliferation of the Sertoli cells with slight blockage of spermatogenesis at seminiferous tubules level in rats treated with (5 mg Pb+50 mg Cd kg⁻¹) diet. H and E x40

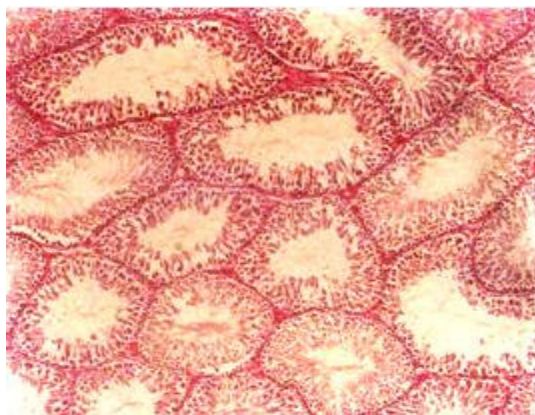


Fig. 6: Normal lumening of the tubules, no evidence of spermatogenesis, with proliferation of the Sertoli cells in rats treated with (25 mg Zn+50 mg Cd mg kg⁻¹) diet. H and E x40

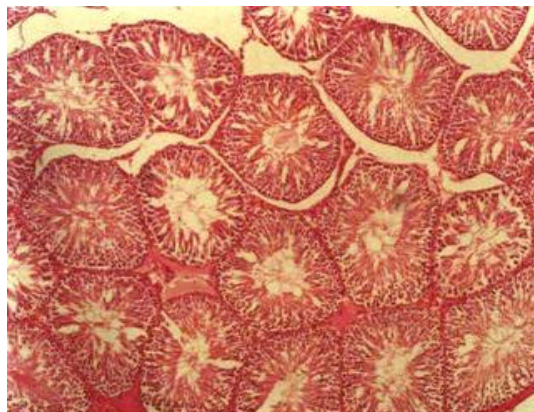


Fig. 7: Slight blockage of spermatogenesis at seminiferous tubules level with some maturation arrest and proliferation of the Sertoli cells in rats treated with (5 mg Pb+25 mg Zn kg⁻¹) diet. H and E x40

with (25 mg Zn+50 mg Cd mg kg⁻¹) diet, indicated normal lumening of the tubules, but no evidence of spermatogenesis, with proliferation of the Sertoli cells. Treatment of rats with (5 mg Pb+25 mg Zn kg⁻¹) diet caused slight blockage of spermatogenesis at seminiferous tubules level with some maturation arrest and proliferation of the Sertoli cells (Fig. 7).

DISCUSSION

All groups treated with Cd, Pb singular or mixture doses indicated severe loss of hair and weight with testicular enlargement, which reflects protein loss and increase division of testicular cells. When Zn is introduced with Cd and Pb doses, these groups showed slight hair and weight loss, which explains the antioxidant effect of Zn. Zinc, is known to be antagonist to both Cd and Pb toxicity. Chelation of zinc ions affects sperm motility in man, rat and dogs. The group treated with Zn showed improvement of the general appearance with increases of weight and activity (Bremner *et al.*, 1976).

Histopathological study of rats group dosed with Cd 100 mg kg⁻¹ diet, revealed moderate blockage of spermatogenesis at seminiferous tubules level, resulted from the toxicity of increased blood Cd level (alone 0.06 versus 0.25, p<0.01), or with Pb element (0.08 versus 0.23, p<0.05), that consumed the antioxidant element Zn and as a consequence blocked the seminiferous tubules. Cd exerts an important action on Sertoli cell proliferation and differentiation. It was shown that cadmium affects Sertoli cell activity by decreasing both synthesis and releasing of inhibin. This data confirm that the severity of cadmium-induced damage at the testicular level. These complications may end with reduction of sperm count (oligospermia), or in severe cases complete deletion of the germ cells (Omu *et al.*, 1995).

Treatment of rats with Pb 5 mg kg⁻¹ diet causes increased level of toxic element Pb in blood alone (0.8 versus 3.5, p<0.05) or with Cd element (0.8 versus 3.5 µg L⁻¹, p<0.01), is in accordance to Batra *et al.* (2004), that deduced appreciable decline in fertility status of male Portan rats by exposing to Pb oral does. Lead is a classical example of a toxicant that directly affects the neuroendocrine and reproductive system (Batra *et al.*, 2004). Elevated blood lead caused defective spermatogenesis and maturation arrest and revealed severe blockage of spermatogenesis at seminiferous tubules level with proliferation of the Sertoli cell. Decreased level

of Zn in this group caused partial or complete maturation arrest and -in severe case- germ cell aplasia due to proliferation of the sertoli cell. In best condition disrupt of spermatogenic process (Pizent *et al.*, 2003).

Rats treated with 25 mg Zn kg⁻¹ diet showed, slight decreased of both blood Cd and Pb level, with increased number of germs cells and developing spermatide at seminiferous tubules level. The significant increased of Zn level (0.16 versus 3.1 mg dL, n = 6, p<0.01) activates secretion and action of testosterone and enables the body to burden the toxicity of other trace elements, with increased efficiency of spermatogenic machinery and increased number of germ cells in the seminiferous tubules (Pizent *et al.*, 2003). Group treated with (5 Pb+50 Cd) mg kg⁻¹ diet showed significant increased of both blood Cd and Pb level that caused slight blockage of spermatogenesis at seminiferous tubules level with partial maturation arrest and polyeriferation of the sertoli cells. Low level of Zn resulted from utilization by Cd and Pb. The combined toxic action of these elements (Cd, Pb) affects germ cell maturation and the proliferation of the sertoli cell, which affect the germ cell development (Damewood and Grochow, 1986).

The group treated with (25 Zn+50 Cd) mg kg⁻¹ diet showed Cd accumulation in the testes leading to slowing of spermatogenesis, proliferation of Sertoli cells, a slight increase in blood Cd. These data were conforming to other published work (Comhaire, 1991). Rat treated with (5 Pb+25 Zn) mg kg⁻¹ diet showed Pb accumulation in the testes leading to blockage of spermatogenesis at seminiferous tubules level, with some maturation arrest and polyeriferation of the sertoli cells (Comhaire, 1991).

CONCLUSION

Treatment of the albino rats with cadmium and lead, blocked the spermatogenesis process, arrested the sperm's maturation and proliferated the sertoli cells. In contrast, doses with zinc improved germ cells development and number.

ACKNOWLEDGMENTS

We thank the technologists of the Center of Central Veterinary Research Laboratories, Soba Khartoum, Sudan and the technologists of Al Neelain University. Great thanks are due to the Postgraduate Collage, University Al Neelain for financial support of this research.

REFERENCES

- Bancroft, J.D., A. Stevens and D.R. Turner, 1996. Theory and Practice of Histological Techniques. 4th Edn., Churchill Livingstone, London.
- Batra, N., B. Nehru and M.P. Bansal, 2004. Reproductive potential of male Portan rats exposed to various levels of lead with regard to zinc status. *Br. J. Nutr.*, 91: 387-391.
- Bishop, M.L., J.L. Duben-Engelkirk and E.P. Fody, 1996. Clinical Chemistry, Principle, Procedure, Correlation. 3rd Edn., Lippincott Williams and Wilkins, Philadelphia, New York. USA, pp: 279-288.
- Bremner, I., B.W. Young and C.F. Mills, 1976. Protective effects of zinc supplementation against copper toxicity in sheep. *Br. J. Nutr.*, 36: 551-561.
- Comhaire, F., 1991. The pathogenesis of epididymo-testicular dysfunction in varicocele: Factors other than temperature. *Adv. Exp. Med. Biol.*, 286: 281-287.
- Damewood, M.D. and L.B. Grochow, 1986. Prospects for fertility after chemotherapy or radiation for neoplastic disease. *Fertility Sterility*, 45: 443-459.

- Elinder, C.G., T. Kjellstrom, L. Friberg, B. Lind and L. Linman, 1976. Cadmium in kidney cortex, liver and pancreas for Swedish autopsies. *Arch. Environ. Health*, 31: 292-302.
- Ellenhorn, M.J., 1997. *Ellenhorn's Medical Toxicology: Diagnosis and Treatment of Human Poisoning*. 2nd Edn., Lippincott Williams and Wilkins, New York, ISBN-10: 068323093X, pp: 2047.
- Goldman, L.A.A., 2000. *Cecil Textbook of Medicine*. 21st Edn., W.B. Saunders, New York, ISBN-10: 072167996X, pp: 71-92.
- Inslar, V. and B. Lunenfeld, 1993. *Infertility: Male and Female*. 2nd Edn., Charchill Livingstone, UK., London, pp: 739.
- Marshall, W.J., 1995. *Clinical Chemistry*. 3rd Edn., MOSPY, London, UK., ISBN: 10: 0723434557.
- Morton, B., J. Harrigan-Lum and L. Albagli, 1974. The activation of motility in quiescent hamster sperm from the epididymis by calcium and cyclic nucleotides. *Biochem. Biophys. Res. Commun.*, 56: 372-379.
- Omu, A.E., H. Dashti, A.T. Mohamed and A.B. Mattappallil, 1995. Significance of trace elements in seminal plasma of infertile men. *Nutrition*, 11: 502-505.
- Osman, K., A. Schutz, B. Akesson, A. Maciag and M. Vahter, 1998. Interactions between essential and toxic elements in lead exposed children in Katowice, Poland. *Clin. Biochem.*, 1: 657-665.
- Pizent, A., J. Jurasovi and S. Telisman, 2003. Serum calcium, zinc and copper in relation to biomarkers of lead and cadmium in men. *J. Trace Element Med. Biol.*, 17: 199-205.
- Public Health Service, 2000. *Healthy People 2000: National Health Promotion and Disease Prevention Objectives*. US Department of Health and Human Services, Washington DC.
- Rutstein, S. and I. Shah, 2004. *Infecundicity, Infertility and Childlessness in Developing Countries*. ORC Macro and the World Health Organization, Calverton, Maryland, USA.
- Zorbas, Y.G., Y.A.N. Yaroshenko, N.K. Kuznetsov and A.L. Ivanov, 1997. Daily zinc supplementation effect on zinc deficiency in rats during prolonged restriction of motor activity. *Biol. Trace Element Res.*, 60: 101-113.